

## Article

# Familial Case of Porphyria with an Epileptic Seizure in the Moscow Region

Artur Latypov<sup>1</sup>, Sergey Kotov<sup>1</sup>, Elena Proskurina<sup>1</sup>, Olga Sidorova<sup>1\*</sup>, Alexey Kotov<sup>1</sup>.

<sup>1</sup> Moscow Regional Research Clinical Institute, Moscow, Russia;

\* Correspondence: sidorovaop2019@mail.ru

[a.latypov@monikiweb.ru](mailto:a.latypov@monikiweb.ru), <https://orcid.org/0009-0006-0064-0448> (A.L.)

[kotosv@yandex.ru](mailto:kotosv@yandex.ru), <https://orcid.org/0000-0002-8706-7317> (S.K.)

[alberus17@gmail.ru](mailto:alberus17@gmail.ru), <https://orcid.org/0009-0002-4865-433X> (E.P.)

[sidorovaop2019@mail.ru](mailto:sidorovaop2019@mail.ru), <https://orcid.org/0000-0003-4113-5799> (O.S.)

[kotosv@yandex.ru](mailto:kotosv@yandex.ru), <https://orcid.org/0000-0002-8706-7317> (A.K.)

**Citation:** Latypov A, Kotov S, Proskurina E, Sidorova O, Kotov A. Familial case of porphyria with an epileptic seizure in the Moscow region. *Otorhinolaryngology, Head and Neck Pathology (ORLHNP)*. 2023; 2 (2): 42-49.

<https://doi.org/10.59315/ORLHNP.2023-2-2.42-49>

Academic Editor: Valentin Popadyuk

Received: 03.05.2023

Revised: 20.07.2023

Accepted: 20.07.2023

Published: 30.07.2023

**Publisher's Note:** International Society for Clinical Physiology and Pathology (ISCPP) stays neutral with regard to jurisdictional claims in published maps and institutional affiliations.

**Copyright:** © 2023 by the authors. Submitted for possible open access publication.

**Abstract:** Objective a clinical case of a 37-year-old patient with familial acute porphyria is presented (the patient's sister died at the age of 28 during an attack of acute porphyria). Material and methods: we used a qualitative urine test for porphyria with Erdich reagent and quantitative determination of porphyrins (porphobilinogen and delta-aminolevulinic acid) on a spectrophotometer "Hitachi 3900". Results. The attack began with pain in the abdomen and lower back, tachycardia, arterial hypertension during menstruation. After taking ketorol and surgical intervention, tonic-clonic convulsions developed with involuntary release of pink urine. CT of the brain shows signs of ischemic cerebrovascular accident in the parietal region of the right hemisphere. There was a decrease in the level of hemoglobin in the blood and APTT. A urine test for porphyria was positive. Porphobilinogen and delta-aminolevulinic acid in the blood are elevated. After the appointment of glucose at a dose of 300 g of dry matter per day in an oral solution, the condition improved. Conclusion. The presented case demonstrates the difficulties in diagnosing and managing patients with acute porphyria, despite the awareness of the attending physicians about this disease. The patient developed an epileptic seizure and brain damage according to CT, which could be posterior reversible encephalopathy. To improve the efficiency of diagnosis and treatment of porphyria in all laboratories, a simple and cheap qualitative urine test for porphyria with Ehrlich's reagent should be organized and Hitachi 3900 spectrophotometers should be purchased at regional medical centers. Informed Consent Statement: Informed consent was obtained from all subjects involved in the study.

**Keywords:** porphyria; epileptic seizure; porphobilinogen; delta-aminolevulinic acid; posterior reversible encephalopathy.

## 1. Introduction

Acute porphyrias are a group of genetically determined diseases associated with the heme biosynthesis cycle, having an acute, induced onset, a progressive nature of the course, which is based on excessive accumulation of metabolites of porphyrin metabolism [1]. An acute attack is provoked by various factors - starvation, alcohol intake, porphyrinogenic drugs.

In Finland, the prevalence of acute intermittent porphyria is 1:60,000 (Kauppinen R et al., 2002) [2]. J. Bustos et al. report a prevalence of acute intermittent porphyria of 1 per 2000 people [3]. In France, 1:1675 latent carriers of this disease were identified among healthy donors (Nordmann Y, 1997) [4]. In the genomic database, the number of cases of mutations in porphyria genes is approximately 1:1500 [5,6].

Porphyrins are involved in heme synthesis (Figure 1). In porphyria, due to a mutation in the genes encoding the enzyme involved in the synthesis of heme, under the influence of unfavorable factors, the metabolism of porphyrins is disturbed and their derivatives accumulate. All patients have elevated levels of porphobilinogen and delta-aminolevulinic acid in the urine.

Porphyria is a hereditary disease caused by a mutation in the genes involved in the heme formation cycle. 8 enzymes are involved in heme biosynthesis. Mutation in these genes involved in porphyrin metabolism leads to the accumulations of porphyrins - heme precursors (delta-aminolevulinic acid, porphobilinogen) under the influence of a provoking factor (starvation, taking drugs contraindicated in porphyria).



Porphyrins have a toxic effect on the nervous system. Initially, unmyelinated fibers of the autonomic nervous system are affected, which leads to dynamic intestinal obstruction due to spasm of some sections of the intestine and paresis of others. This is accompanied by pain in the abdomen. Pain in the chest and limbs are radicular. After 7-10 days, myelin fibers are affected and peripheral paresis develops according to the type of polyneuropathy.

Epileptic seizures are possible [8]. Usually these are tonic-clonic and focal seizures with impaired consciousness. Status epilepticus with seizures and partial continuous epilepsy are rare [9]. High probability of a lethal outcome of the disease with late diagnosis [10].

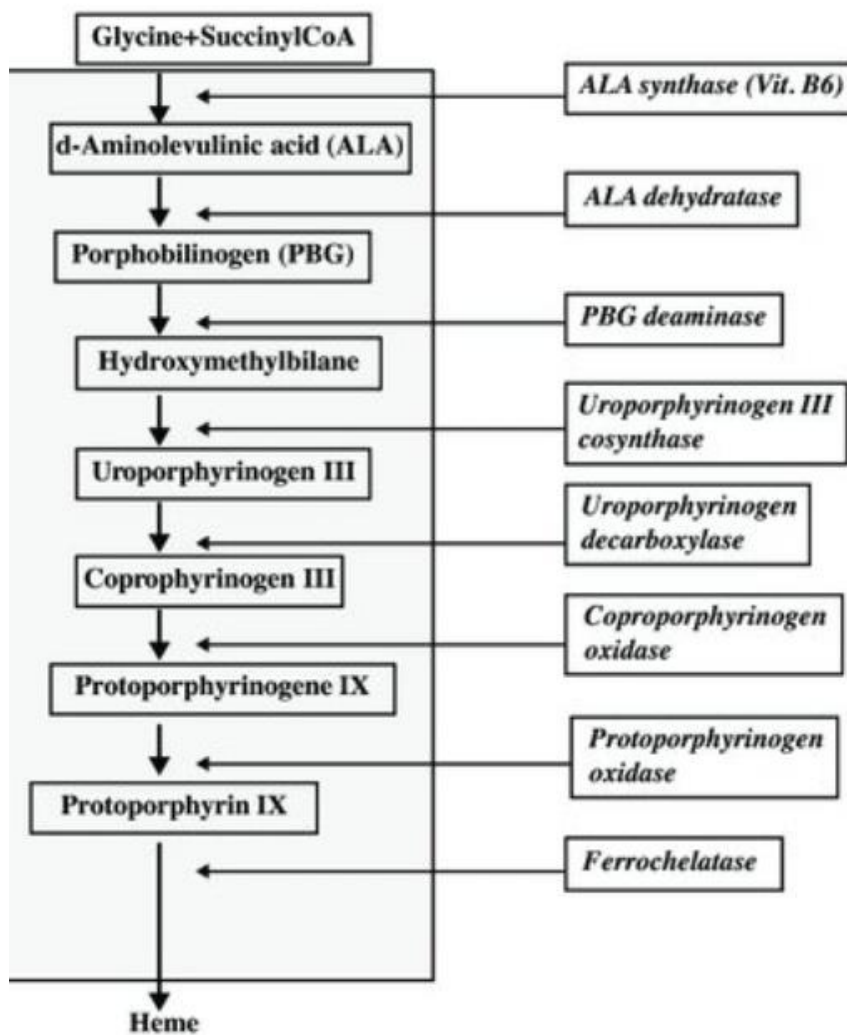


Figure 1. Metabolism of porphyrins [7].

Timely diagnosis of this pathology is important for the appointment of glucose (200-400 g of dry matter per day), as a blocker of the aminolevulinic acid synthetase enzyme. If this is not enough, heme arginate (normosang) is prescribed. It is necessary to clarify the possibility of prescribing drugs on the website of the National Research Center for Hematology of the Ministry of Health of Russia <http://www.critical.ru/consult/pages/porphyria/prodlistsimple.htm>. There is also a 'porphyria drug' website.

It is important to examine the relatives of patients, since the disease is transmitted in an autosomal dominant manner and the children of patients, brothers and sisters are at high risk of developing acute porphyria. The latent phase of the disease in them can turn into a potentially life-threatening acute period [11]. There is also secondary porphyria in lead poisoning, alcohol surrogates. It is important to examine the relatives of patients, since the disease is transmitted in an autosomal dominant manner and the children of patients, brothers and sisters are at high risk of developing acute porphyria. The latent phase of the disease in them can turn into a potentially life-threatening acute period [11]. There is also secondary porphyria in lead poisoning, alcohol surrogates.



For the treatment of porphyria, glucose is used, which inhibits the activity of the enzyme aminolevulinic acid synthetase [12]. During the day, 200-400 g of dry matter glucose is prescribed. In the absence of improvement within three days, as well as in the case of a severe course of an acute attack of porphyria, intravenous heme arginate is administered at a dose of 3 mg/kg of body weight for 4-7 days. Heme arginate, according to the feedback principle, stops the development of metabolites of pores. And this leads to normalization of the patient's condition. Heme arginate is injected into 100-150 ml of physiological saline intravenously by drip rapidly, but not less than for 30 minutes in a dark glass container, protected from light system. Usually - 4 introductions. The central vein or vein of the forearm should be used.

A new medicine, gevosiran, has been developed to prevent acute attacks of porphyria. It disables the mRNA encoding aminolevulinic acid synthetase I. The medicine provides prevention and reduction in the frequency of severe attacks of acute hepatic porphyria, controls chronic symptoms, and facilitates the course of the disease [13, 14]. New approaches are being developed for the prevention of acute attacks and the treatment of the disease, based on the stabilization of HMBS and the regulation of proteostasis [15].

Early identification of patients at risk of developing acute porphyria is important [16]. Timely laboratory diagnosis is important, including for presymptomatic carriers of the disease gene [17]. Timely diagnosis helps to prevent severe consequences of an acute attack of the disease [18,19].

Relatives of patients should be examined. Conduct DNA diagnostics to detect mutations in the genes encoding porphyria. The level of porphyrins in the urine of carriers of mutations in the porphyria genes should also be monitored.

It is also important to diagnose an acute attack of porphyria in a timely manner. The disease should be suspected if the patient has unexplained abdominal pain and at least one of the following: pain in the limbs, nausea, vomiting, anxiety, sleep disturbance, epileptic seizure, weakness in the limbs, dark or reddish urine, constipation or diarrhea, hallucinations .

An acute attack of porphyria requires a quick examination of the patient for his treatment. Therefore, it is important to identify carriers of the porphyria gene. When sequencing of newborns is included in the future, detection of mutations in porphyria genes in them will allow controlling the level of porphyrins in the urine, prescribing preventive treatment, and preventing an attack of acute porphyria. And, thus, reduce mortality in this disease.

It is important to provide medical institutions with affordable laboratory diagnostics of porphyria (urine test for porphyria with Erdich's reagent and quantitative determination of porphyrins in urine (delta-aminolevulinic acid and porphobilinogen) using a Hitachi 3900 spectrophotometer.

## 2. Patients and Methods

### 2.1. Patient.

A women with porphyria from a family in which her own sister died during an acute attack of porphyria.

### 2.2. Urine test for porphyria with Ehrlich's reagent.

The diagnosis porphyria was clarified using a qualitative urine test for porphyria with Ehrlich's reagent. Ehrlich's reagent is a solution of p-dimethylaminobenzaldehyde 20 g/l in a mixture of glacial acetic and perchloric acids. When porphobilinogen interacts with Ehrlich's reagent, porphobilinogen aldehyde is formed, which has a red color.

During the determination of porphobilinogen, the patient's urine and Ehrlich's reagent are taken in a ratio of 1:1. The reaction should be considered positive if in the first 5 minutes after the addition of Ehrlich's reagent there was a sharp change in color (redness)

### 2.3. Quantitative determination of porphyrins in the urine

After qualitative urine test for porphyria with Ehrlich's reagent, followed by quantitative determination of porphyrins in the urine using a Hitachi 3900 spectrophotometer at a wavelength of 555 nm.

## 3. Results

A 37-year-old patient was admitted to the gynecology department with complaints of recurrent pain in the lower back, lower abdomen, increased blood pressure to 150/80 mm Hg. Art. The last 8 months there was an exacerbation of cystitis. The patient took monural, furadonin. The patient's sister died at the age of 28 during an attack of acute porphyria.

On examination, blood pressure was 150/70 mm Hg. Art., the number of heartbeats 150-160 in 1 minute, arrhythmia. The abdomen was soft, slightly painful in the navel. There was mucosa



discharge from the genital tract (the last days of menstruation). Ultrasound of the abdominal cavity and small pelvis revealed no pathology. Acute salpingo-oophoritis was diagnosed. The patient received anti-inflammatory therapy - cefazolin, metronidazole, ketorol. But the pain persisted. Culdocentesis was performed under local anesthesia with novocaine, after which during the evening she felt weakness, "spots" before her eyes. The next day, tonic-clonic convulsions developed. There was involuntary urination, pink urine. In the blood test, hemoglobin is 105 g/l (normally 120-140 g/l), APTT is 14 seconds (normally 21.1-36.5 seconds). Acute intermittent porphyria was diagnosed.

The patient was transferred to the intensive care unit. Glucose was prescribed at a dose of 300 g of dry matter per day in oral solution. Condition of the patient was stabilized, she was transferred to the therapeutic department. Drotaverine was prescribed to reduce abdominal pain. The patient also received ceftriaxone, metranidazole, B vitamins, omez, velferrum, bisoprolol, enalapril. Pain in the legs appeared 10 days after the onset of the disease. The patient was transferred to the neurology department. In the neurological department, she complained of weakness in the legs, pain in the abdomen, lower extremities, increased blood pressure. On examination, blood pressure was 130/80 mm Hg. Art., the number of heartbeats 82 in 1 minute on the background of enalapril and bisoprolol. The abdomen is of normal shape, painful on palpation. In the neurological status - cranial nerves without focal symptoms. The strength of the muscles of the limbs is reduced to 4 points. There was hypotonia of the muscles of the lower extremities. Tendon reflexes from the hands were brisk. The knee reflexes were reduced. The Achilles reflexes were absent. Violation of sensitivity by polyneuritic type. Finger-to-nose and heel-to-knee tests were performed with a slight overshoot.

ECG: atrial paroxysmal tachycardia 150 in 1 minute. A CT scan of the brain was performed. The CT picture may correspond to an ischemic type of cerebrovascular accident in the parietal region of the right hemisphere of the brain. Acute period? Atrophic changes in the cerebral cortex.

A qualitative urine test for porphyria with Ehrlich's reagent is positive. Quantitative determination of porphyrins in urine: porphobilinogen - 131.1 mg / l (normal 0.0 - 3.4 mg / l), delta-aminolevulinic acid 26.3 mg / l (normal 1.5-7.5 mg / l).

Diagnosis: acute porphyria. Epileptic syndrome (for the first time identified a single convulsive attack with loss of consciousness). Violation of cerebral circulation in the basin of the right cerebral artery according to the ischemic type of unknown statute of limitations. Polyneuropathy.

The patient received glucose at a dose of 300 g of dry matter dissolved in water, orally during the day, B vitamins (B1, B6, B12), gabapentin, enalapril, bisoprolol. The condition has improved. The patient was transferred to the National Research Center for Hematology of the Ministry of Health of Russia for treatment with heme arginate (normosang).

#### 4. Discussion

The presented a patient whose disease began with abdominal pain during menstruation, increased blood pressure. After the surgical intervention and taking non-steroidal anti-inflammatory medicine tromethamin, the condition worsened, tonic-clonic convulsions appeared with involuntary urination of pink urine.

Taking into account the anamnesis (his sister died during an acute attack of porphyria) and the clinical picture of the disease (abdominal pain, tachycardia, pink urine), acute porphyria was diagnosed. After the start of glucose intake, the condition improved. Confirmatory laboratory diagnostics (qualitative urine test for porphyria with Ehrlich's reagent) was carried out on the 12th day from the onset of the disease (on the 2nd day of hospitalization in the neurological department). Due to the fact that laboratory confirmation of the diagnosis by quantitative determination of porphyrins in urine is carried out only at the National Research Center for Hematology of the Ministry of Health of Russia, this study was carried out after 1 week of hospitalization in the neurological department and on the 19th day from the onset of the disease. Since the treatment of the disease with glucose began already on the 7th day from the onset of the disease, the patient's condition did not worsen. But complete recovery required the introduction of heme arginate (normosang), for which the patient was transferred to the Federal State Budgetary Institution National Research Center for Hematology of the Ministry of Health of Russia. Discussion: a patient is presented whose disease began with abdominal pain during menstruation, increased blood pressure. After the surgical intervention and taking tromethzmin, the condition worsened, tonic-clonic convulsions appeared with involuntary urination of pink urine. Taking into account the anamnesis (his sister died during an acute attack of porphyria) and the clinical picture of the disease (abdominal pain, tachycardia, pink urine), acute porphyria was diagnosed.

After the start of glucose intake, the condition improved. Confirmatory laboratory diagnostics (qualitative urine test for porphyria with Ehrlich's reagent) was carried out on the 12th day from the onset of the disease (on the 2nd day of hospitalization in the neurological department). Due to the fact that laboratory confirmation of the diagnosis by quantitative determination of porphyrins in urine is carried out only at the National Research Center for Hematology of the Ministry



of Health of Russia, this study was carried out after 1 week of hospitalization in the neurological department and on the 19th day from the onset of the disease. Since the treatment of the disease with glucose began already on the 7th day from the onset of the disease, the patient's condition did not worsen. But complete recovery required the introduction of heme arginate (normosang), for which the patient was transferred to the Federal State Budgetary Institution National Research Center for Hematology of the Ministry of Health of Russia.

Changes on CT scan of the brain may be due to a stroke or it is a posterior reversible encephalopathy that occurs during an attack in acute porphyria [20, 21]. An epileptic seizure in patients with porphyria may be due to posterior reversible encephalopathy. The exact mechanism of posterior reversible encephalopathy syndrome is not fully understood. It is thought to be related to a problem with the blood vessels in the brain. There are several theories as to why these blood vessels may become inappropriately permeable and cause the surrounding brain tissue to swell. According to the "Vasogenic" theory, high blood pressure interferes with the normal ability of the blood vessels in the brain to maintain normal cerebral blood flow. Increased pressure damages the endothelial layer, the blood-brain barrier and leads to edema. The tendency to damage the posterior part of the brain can be explained by the reduced density of sympathetic innervation in the posterior circulation compared to the anterior circulation [22]. The "vasogenic" theory probably explains about 50% of cases of posterior reversible encephalopathy syndrome in which there was a significant increase in blood pressure [23]. The "cytotoxic" theory suggests that edema is caused by direct damage to cells by toxins. "

## 5. Conclusions

The presented case demonstrates the difficulties in diagnosing porphyria. A patient with acute pain in the abdomen and lower back was hospitalized first in the gynecology department, then was transferred to the intensive care unit. After that, she was in the therapy department. And then she entered the department of neurology. The presence of the patient in various clinical departments is associated with the development of the pathological process in acute porphyria. The patient had an attack of pain during menstruation. Initially, the vegetative ganglia are affected, paresis and intestinal spasm occur. The patient has abdominal pain during menstruation, which can provoke the development of an acute attack of porphyria. The surgical intervention, the use of a non-steroidal anti-inflammatory drug led to the progression of the pathological process and the development of an epileptic seizure, after which the patient was transferred to the intensive care unit. When a change in the color of urine was revealed, and there was also information about porphyria in a sister, then the diagnosis was already clear. And the patient was transferred to the therapy department. Glucose was prescribed. But, probably, this was not enough, since the disease developed further, weakness appeared in the legs, polyneuropathy developed, which indicates damage to the myelin sheaths of peripheral nerves. However, unlike the patient's sister, she survived despite a severe attack of acute porphyria, as the diagnosis was made on time, although she had to be transferred to the federal center for the administration of heme arginate.

The presented case demonstrates the difficulties in diagnosing and managing patients with acute porphyria, despite the awareness of the attending physicians about this disease. Therefore, in order to improve the care of patients with porphyria, a number of organizational measures are needed. Acute hepatic porphyria (AHP) can cause severe neurological symptoms affecting the central, autonomic, and peripheral nervous systems. Due to their relative rarity and their chameleon-like appearance, delayed diagnosis and misdiagnosis, including Guillain-Barré syndrome, are common [24,25]. Physicians should be aware of porphyrias, which can cause unexplained gastrointestinal and neurological diseases [26]. Abdominal pain is a common reason for emergency room visits, with many patients not being definitively diagnosed based on their symptoms. Non-gastrointestinal causes, including porphyria, should be considered in the treatment of abdominal pain.

The availability of laboratory diagnostic methods is necessary to confirm the diagnosis of porphyria. The urine test for porphyria with Ehrlich's reagent is a screening test for the determination of indole compounds, which include porphobilinogen. In porphyria, porphobilinogen accumulates in large quantities and is excreted in the urine. Porphobilinogen is one of the main markers of an acute state (attack) in porphyrias, the pathogenesis of which is based on disturbances in heme synthesis caused by a deficiency of one of the enzymes of its synthesis and urinary excretion of precursors, protoporphyrins. Due to the fact that clinically acute conditions in porphyrias are characterized by a complex of therapeutic, neurological and psychiatric symptoms, such as abdominal pain, tachycardia, arterial hypertension, behavioral changes, epileptic seizures, coma, paresis of the respiratory muscles, etc., the determination of porphobilinogen in urine is most appropriate in neurological, psychiatric and surgical hospitals.

At the same time, with porphyria, the use of a number of widely used drugs (barbiturates, ethanol, chlorpropanide, sulfanides, etc.) is unacceptable, since they can cause an attack of por-




phyria. Therefore, the determination of porphobilinogen is the basis for timely diagnosis and adequate therapy, since at present there is a medicine hematin arginate (normosang) that can stop the attack in porphyrias.

A qualitative urine test for porphyria with Ehrlich's reagent is a cheap method that takes a small amount of time to perform. The test is a screening test and requires confirmation by a more expensive and time-consuming method, the quantitative determination of porphyrins in urine using a Hitachi 3900 spectrophotometer.

Ehrlich's reagent is a solution of p-dimethylaminobenzaldehyde 20 g/l in a mixture of glacial acetic and perchloric acids. When porphobilinogen interacts with Ehrlich's reagent, porphobilinogen aldehyde is formed, which has a red color.

During the determination of porphobilinogen, the patient's urine and Ehrlich's reagent are taken in a ratio of 1:1. The reaction should be considered positive if in the first 5 minutes after the addition of Ehrlich's reagent there was a sharp change in color (redness) (Figure 2).



**Figure 2.** Positive qualitative urine test for porphyria with Ehrlich's reagent (a, b, c)

A urine test for porphyria with Ehrlich's reagent should be in the structure of all medical institutions. If laboratory diagnosis is carried out centrally, it is necessary to ensure that urine is frozen and delivered in a cooler bag with a cooling element, since porphobilinogen is rapidly destroyed and this can lead to the fact that porphyria will not be diagnosed.

To quantify porphyrins in urine, a Hitachi 3900 spectrophotometer is used. Total porphyrins are determined in daily urine and delta-aminolevulinic acid and porphobilinogen are determined in single urine. Porphobilinogen is rapidly degraded. Therefore, the determination of delta-aminolevulinic acid may be more informative for the diagnosis of porphyria. Urinary porphyrin quantitation can be used to monitor urinary porphyrin levels by detecting porphobilinogen alone.

The method for the quantitative determination of porphobilinogen and delta-aminolevulinic acid in urine is based on their separation by absorption (absorption) of solutions on columns with



an ion-exchange resin (ion-exchange column chromatography), followed by the use of Erlich's reagent and measurement of the results on a spectrophotometer at a wavelength of 555 nm to detect porphyrins.

Given that the spectrophotometer is an expensive device, it is advisable to place it in medical centers. It is necessary to organize the delivery of urine for examination in a cooler bag with a cooling element, so that there is no destruction of porphyrin metabolites and the diagnosis of porphyria is not missed. Daily urine should be collected in a refrigerator so that the metabolites of the porphyrins are not destroyed. Single urine and a small amount from daily urine can be frozen and stored for a long time for further research.

In connection with the development of preventive medicine, the most significant effect will be the identification of carriers of the porphyria gene among newborns with the expansion of mass screening of newborns using the sequencing method. If carriers of mutations in the porphyria genes are identified, recommendations will be given on the contraindication of the use of drugs that worsen the course of porphyria. Recommendations will also be given on the exclusion of alcohol in the future, that fasting should be avoided. Carriers of mutations in the porphyria gene will be warned to monitor the level of porphyrins in the urine, if they increase, it is necessary to take glucose to prevent an acute attack. These patients will be prescribed gevosiran to prevent acute attacks of porphyria. At present, when sequencing has not yet been included in the list of mass newborn screening methods, it is necessary to expand the information of doctors about porphyria and make the diagnosis and treatment of patients with an acute attack of porphyria accessible.

To improve the efficiency of diagnosis and treatment of porphyria in all laboratories, a simple and cheap qualitative urine test for porphyria with Ehrlich's reagent should be organized and Hitachi 3900 spectrophotometers should be purchased at regional medical centers. Informed Consent Statement: Informed consent was obtained from all subjects involved in the study.

**Author Contributions:** Conceptualization, A. Latypov, S. Kotov, E. Proskurina; methodology, A. Latypov, writing—original draft preparation, – E. Proskurina, O. Sidorova, A. Kotov; writing—review and editing, A. Latypov, S. Kotov, E. ; visualization, O. Sidorova, A. Kotov. All authors have read and agreed to the published version of the manuscript.”

**Funding:** public funding.

**Informed Consent Statement:** Informed consent was obtained from all subjects involved in the study.

**Conflicts of Interest:** The authors declare no conflict of interest.

**The use of artificial intelligence:** the article is written without the use of artificial intelligence technologies.

## References

1. Phillips JD Heme biosynthesis and the porphyrias. *Mol Genet Metab.* 2019; 128(3):164-177.
2. Kauppinen R. Molecular and Biochemical Studies of Acute Intermittent Porphyria in 196 Patients and Their Families. *Clinical Chemistry.* 2002; 48(11):1891-1900.
3. Bustos J, Vargas L, Quintero R Acute intermittent porphyria: A case report. *Biomedica.* 2020; 40(1):14-19.
4. Nordmann Y, Puy H, Da Silva V et al. Acute intermittent porphyria: prevalence of mutations in the porphobilinogen deaminase gene in blood donors in Franc. *J Intern Med.* 1997; 242(3):213-7.
5. Chen B, Solis-Villa C, Hakenberg J et al. Acute Intermittent Porphyria: Predicted Pathogenicity of HMBS Variants Indicates Extremely Low Penetrance of the Autosomal Dominant Disease. 2016; 37(11):1215-1222.
6. Lenglet H, Schmitt C, Grange T et al. From a dominant to an oligogenic model of inheritance with environmental modifiers in acute intermittent porphyria. *Hum Mol Genet.* 2018; 27(7):1164-1173.
7. Ventura P, Brancalonei V, Di Pierro E et al. Clinical and molecular epidemiology of erythropoietic protoporphyria in Italy. *European journal of dermatology.* 2020; 30(5):532-540.
8. Redmond J, Fazio T, Buzzard K Acute intermittent porphyria presenting with first episode seizure and rhabdomyolysis. *Acta Neurol Belg.* 2022.
9. Sara D, Shubhang KB, Devika MD, Andrew RP, Harn JS, Brent PG, Joseph FD, Joseph IS. Nonconvulsive status epilepticus secondary to acute porphyria crisis. *Epilepsy Behav Case Rep* 2018; 8(11):43-46.
10. Neeleman R, Musters K, Wagenmakers M et al. Mortality in Pedigrees with Acute Intermittent Porphyria. *Life (Basel).* 2022; 12(12): 2059.
11. Lederer D, Weigand MA, Larmann J Anästhesie bei Patienten mit akuter Porphyrie [Anesthesia in patients with acute porphyria]. *Anaesthesist.* 2022; 71(4):321-330.
12. Castellón Fernández FJ, Solares Fernandez I, Arranz Canales E, et al. Protocol For Patients With Suspected Acute Porphyria. *Rev Clin Esp.* 2020; 3: S0014-2565(20)30022-9.
13. Syed YY, Givosiran A, Review in Acute Hepatic Porphyria. *Drugs.* 2021; 81(7):841-848.
14. Ricci A, Ventura P, Givosiran for the treatment of acute hepatic porphyria. *Expert Rev Clin Pharmacol.* 2022; 15(4):383-393.
15. Bustad HJ, Kallio JP, Vorland M et al. Acute Intermittent Porphyria: An Overview of Therapy Developments and Future Perspectives Focusing on Stabilisation of HMBS and Proteostasis Regulators. *Int J Mol Sci.* 2021; 22(2):675.
16. Heymans B, Meersseman W, Porphyria: awareness is the key to diagnosis! *Acta Clin Belg.* 2022; 77(3):703-709.
17. Di Pierro E, De Canio M, Mercadante R et al. Laboratory Diagnosis of Porphyria. 2021; 11(8):1343.
18. O'Malley R, Rao G, Stein P, Bandmann O, Porphyria: often discussed but too often missed. *Pract Neurol.* 2018; 18(5):352-358.



19. Baidya S, Kandel P, Rajkarnikar S et al. Porphyria: a case report. *J Med Case Rep.* 2022; 16(1):490.
20. Pishchik EG, Rudenko DI, Karpenko AK et al. Posterior Reversible Encephalopathy Syndrome as a Manifestation of an Attack of Acute Intermittent Porphyria. *Neurological Journal*; 2019. 24(1):29-34. (In Russian).
21. R. Sharma R, Sharma N, Synmon B, Hynniewtaya Y Porphyria-induced Postpartum Reversible Posterior Encephalopathy Syndrome. *Indian J Crit Care Med.* 2022; 26(2):728-730.
22. Fischer M, Schmutzhard E. Posterior reversible encephalopathy syndrome. *J Neurol* 2017; 264(8):1608-1616.
23. Liman TG, Siebert E, Endres M, Posterior reversible encephalopathy syndrome. *Current Opinion in Neurology.* 2019. 32(1):p25-35.
24. Gerischer LM, Scheibe F, Nümann A, Köhnlein M, Stölzel U, Meisel A. Acute porphyrias - A neurological perspective. *Brain Behav.* 2021; 11(11):e2389.
25. Valampampil J, Kelgeri C, Vij M et al. Porphyria Mimic: A Note of Caution. *Indian J Pediatr.* 2021; 88(12):1267.
26. Stölzel U, Doss MO, Schuppan D Clinical Guide and Update on Porphyrias . *Gastroenterology.* 2019; 157(2):365-381.e4.

